

Comparison of posterior capsule opacification between a 1-piece and a 3-piece microincision intraocular lens

Ana Prinz,^{1,2} Pia Veronika Vecsei-Marlovits,^{1,2} Dietrich Sonderhof,^{1,2} Paul Irsigler,^{1,2} Oliver Findl,³ Birgit Weingessel^{1,2}

¹Department of Ophthalmology, Hietzing Hospital, Vienna, Austria
²Karl Landsteiner Institute of Process Optimization and QM in Cataract Surgery, Vienna, Austria

³Department of Ophthalmology, Hanusch Hospital, Vienna, Austria

Correspondence to

Dr Birgit Weingessel, Department of Ophthalmology, Hietzing Hospital, Wolkersbergenstrasse 1, Wien 1130, Austria; birgit.weingessel@wienkav.at

Received 21 April 2012

Revised 25 July 2012

Accepted 30 July 2012

Published Online First

5 September 2012

ABSTRACT

Objective To compare the intensity of posterior capsular opacification (PCO) between a 1-piece and a 3-piece microincision cataract surgery intraocular lens (MICS IOL) in a prospective randomised study.

Methods 80 eyes of 40 patients with age-related cataract were enrolled in this study. Each patient received a 1-piece MICS IOL (AF-1 NY-60, Hoya, Tokyo, Japan) in one eye and a 3-piece MICS IOL (AF-1 iMICS Y-60H, Tokyo, Hoya) in the other eye. At the 1-year follow-up, the patients were examined at the slit lamp, visual acuity was determined and standardised high-resolution digital retroillumination images were taken for objective quantification of regenerative PCO using an automated image analysis software (AQUA).

Results The mean regenerative PCO score (1-piece IOL: 0.2, 3-piece IOL 0.3, $p=0.7$) and the neodymium:yttrium-aluminium-garnet laser capsulotomy rate (two cases in 3-piece IOL group; $p=0.5$) were comparable low for both IOLs. Capsular folds occurred significantly more often in the 3-piece IOL group ($p=0.02$).

Conclusions Modification of the MICS IOL from a 3-piece to a 1-piece haptic design caused in short term no significant change in PCO amount. Compared with the 3-piece IOL, the 1-piece IOL led to significantly less capsular folds 1 year after surgery.

INTRODUCTION

Despite the high standard of modern cataract surgery, posterior capsular opacification (PCO) still remains the most frequent long-term complication.¹ PCO is known to be a wound-healing response of the equatorial lens epithelial cells (LEC) and can be clinically differentiated in two types: fibrotic and regenerative. Transdifferentiation of residual LEC into myofibroblasts causes fibrotic PCO, and migration of LEC into the space between capsule and intraocular lens (IOL) with subsequent proliferation causes regenerative PCO. Both types of PCO lead to visual loss, once the visual axis has been involved. Although the treatment of PCO by neodymium:yttrium-aluminium-garnet (Nd:YAG) laser capsulotomy is effective and a relatively simple procedure, it still comprises a few serious complications, such as potential damage of the IOL, cystoid macular oedema or retinal detachment. Moreover, it does not improve the visualisation of the peripheral retina.

Since the Acrysof IOL (Alcon Laboratories, Inc., Texas, USA) has been introduced in the early 1990s, several new foldable multi-piece or single piece IOLs with sharp optic edge design have been

developed. Previous studies depict that the presence of a sharp posterior optic edge is crucial for PCO prevention, whereas the IOL material and haptic design may be of less importance.^{2–5}

In the meantime, due to the refinements in phacoemulsification technology, cataract can be removed through incisions smaller than 2 mm in a procedure called microincision cataract surgery (MICS). The benefits of MICS are reduced surgically induced astigmatism, more stable wound construction and rapid visual rehabilitation.^{6–8} However, this advanced technique requires specific IOLs with special delivery systems which fit through incisions of 2 mm or smaller. The early MICS IOLs showed higher PCO incidence, probably due to hydrophilic acrylic material⁹ and deviation from the common 3-piece or 1-piece open-loop haptic designs.^{10–11} Recently hydrophobic acrylic 1-piece and 3-piece IOLs are finally commercially available for MICS.

The present study compared the development of PCO as well as the clinical outcome between a 1-piece and a 3-piece MICS IOL.

PATIENTS AND METHODS

This prospective randomised patient and examiner-masked clinical trial with intraindividual comparison was performed at the Department of Ophthalmology at the Hietzing Hospital (Vienna, Austria). Forty patients (80 eyes) were recruited consecutively from May 2009 to August 2009. Inclusion criterion was bilateral age-related cataract. Exclusion criteria were history of other ocular diseases or intraocular surgery, laser treatment, glaucoma, retinal pathology and diabetes requiring medical treatment. The study was conducted according to the guidelines of the Declaration of Helsinki and an ethics committee approval was obtained.

Intraocular lens assignment

Each patient received a 1-piece AF-1 iMICS NY-60 IOL (Hoya, Tokyo, Japan) in one eye and a 3-piece AF-1 Y-60H MICS IOL (Hoya, Japan) in the contralateral eye to allow intraindividual comparison. The IOL type in the first operated eye was randomly assigned using sealed envelopes generated by a computer system operated by a person not involved in the trial. The patients and examiners were masked to the allocation, whereas the surgeon was masked to allocation until the time of IOL implantation. In 20 cases, the 1-piece IOL was implanted in the right eye and in 20 cases in the left eye.



► <http://dx.doi.org/10.1136/bjophthalmol-2012-302570>

To cite: Prinz A, Vecsei-Marlovits PV, Sonderhof D, et al. *Br J Ophthalmol* 2013; **97**, 18–22.



Figure 1 The 3-piece (AF-1 iMICS Y-60H, Hoya) intraocular lens (left) and 1-piece (AF-1 NY-60, Hoya, Tokyo, Japan) intraocular lens (right). This figure is only reproduced in colour in the online version.

Both IOLs are made of the same foldable acrylic hydrophobic material with blue-light filter (AF-1(UY)) that attenuates the transmission of visible light in the 400 nm to 500 nm range. Due to their special design for MICS, both lenses allow an injection through a 1.8 mm incision. Both IOL types are identical in terms of their 6 mm optic diameter and 12.5 mm overall diameter, 360° square-edge design and 5° angulated haptic design. The spherical 3-piece Y-60H IOL has haptics made of poly (methyl methacrylate) (PMMA) (figure 1, left). The aspheric single-piece MICS IOL has acrylic haptics with additional supporting PMMA haptic ends (figure 1, right) to prevent the optic-haptic bonding after injection through 2.0 mm cartridge and to provide improved stabilisation and centration of the IOL in the bag. According to the manufacturer, benefits of the novel 1-piece IOL design are preloaded facilitation and the novel aspheric balanced curve optic design.

Surgery was performed by one of five experienced surgeons, where the same surgeon operated both eyes of a patient. To perform standardised small-incision coaxial phacoemulsification technique, a 2.5 mm temporal, single-plane, self-sealing, clear corneal incision was created. The anterior chamber was filled with a viscoelastic substance and a continuous curvilinear capsulorhexis (slightly smaller than the IOL optic diameter) was created to attain a symmetrical 360° rhexis-IOL overlap. After hydrodissection and phacoemulsification, the surgeon was unmasked to IOL type. In all cases, there was a rhexis overlap with the IOL optic along the entire circumference at the end of the surgery. Postoperative treatment consisted of topical tobramycin-dexamethason eyedrops (Tobradex) and ketarolac eyedrops (Acular) four times a day for 4 weeks.

Follow-up examination and image acquisition

A postoperative examination was performed at two appointments 1 year after surgery. At the first occasion, after assessing an uncorrected distance visual acuity (UCVA) and best spectacle corrected distance visual acuity (BCVA) using Early Treatment of Diabetic Retinopathy study (ETDRS) charts, all patients received phenylephrine 2.5% and tropicamide 0.5% drops at least half an hour before they were examined at the slit lamp. Using a

standardised evaluation form, the following parameters were assessed subjectively: IOL position and centration and rhexis-IOL overlap. The amount of anterior capsular opacification (ACO) and of posterior fibrosis (fibrotic PCO) were graded by subjective scale from 0 to 3 (0=clear capsule, 3=severe fibrotic opacification). Finally, the need for an Nd:YAG laser capsulotomy was noted.

At the second occasion, within 1 week after clinical examination, digital retroillumination photographs were obtained with a digital camera (Canon EOS 5D) at the Department of Ophthalmology, Hanusch Hospital in Vienna. This camera was mounted on a modified Zeiss 30 slitlamp (Carl Zeiss Meditec AG) with an external flashlight source, which provides coaxial illumination from the flash pack through a fibreoptic cable to the camera. This system is similar to the system described by Pande *et al.*¹² It provides even illumination over the entire image with relatively small flash artefacts and has high reproducibility.¹³ In this study we used it for documentation of IOL capsular bag position and regenerative PCO. All digital images were transferred to a personal computer and stored for later evaluation.

Image analysis

Since the amount of PCO was of major interest for this study, we used automated image analysis software for objective PCO evaluation. This computer program, Automated Quantification of After-Cataract (AQUA), has been developed at the University of Vienna in cooperation with the Technical University of Graz, Austria. For each patient, digital retroillumination images at 1 year follow-up examination were imported into the program and the region within the capsulorhexis was evaluated. The program detects the capsulorhexis edge semiautomatically (computer aided). The AQUA software calculates the grade of disorder (entropy) of a bitmap. This value is converted to a score between 0 and 10 (0=clear capsule, 10=exceptionally severe PCO). This fully automated system provides a scoring process without any interactive steps and has been previously shown to correlate well with subjective scoring of PCO at the slitlamp.¹⁴

Sample size

The study size was estimated using data from a previous trial that assessed the PCO rate using the same photographic acquisition system and the same PCO analysis system. Aiming for a power at 80% level to detect a difference in PCO score of 0.5 (ie, 5%; possible range: 0–10) at an α level of 5% in a bilateral study design, a sample size of 32 patients was calculated. To account for dropouts of about 25% in this elderly population, 40 patients were included in this study.

Statistics

Statistical analysis was performed with MS Excel and SPSS for Windows (SPSS V.15.0). The results in the 1-piece and 3-piece groups were compared and presented at mean, and SD. To compare means, paired t-tests were applied to the data that could be described by the normal distribution. Binary data were analysed by McNemar and χ^2 test, respectively. A p value of 0.05 or less was considered significant.

RESULTS

Forty patients were recruited and only one patient was excluded. In this single case, after uneventful cataract removal and a 3-piece IOL implantation, a posterior capsular tear occurred while IOL unfolded in the bag. All 39 included patients were available for 1 year follow-up examination. The age of the study patients was 71.7 ± 7.1 years (mean \pm SD).

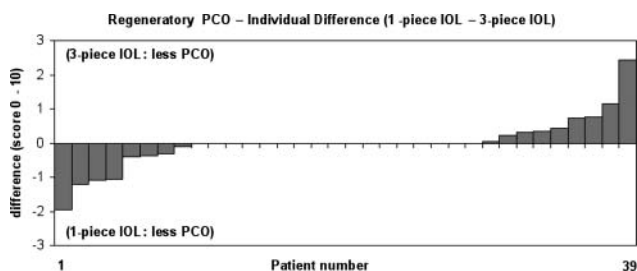


Figure 2 Intraindividual difference in regenerative posterior capsular opacification in all patients (n=39) 1 year after surgery.

PCO in digital retroillumination images from 1-year follow-up was evaluated using AQUA software. A mean objective PCO score \pm SD (scale 0–10) of 0.2 ± 0.5 was found for the 1-piece IOL group and a score of 0.3 ± 0.5 was found for the 3-piece IOL group. There was no significant difference between the two groups ($p=0.7$). In 26 eyes from the 1-piece IOL group and 27 eyes of the 3-piece IOL group no regenerative PCO has been detected 1 year after surgery (figure 2). Only two eyes in the 3-piece IOL group and none in the 1-piece IOL group required Nd:YAG capsulotomy following 1 year examination ($p=0.5$, McNemar test).

Similar to the objective image analysis findings, there was no significant difference neither in amount of fibrotic PCO (scale 0–3) nor in incidence of the two subtypes of fibrotic PCO (sand dunes and wrinkling) between the groups (1-piece group: 0.7 ± 0.59 ; 3-piece group: 0.7 ± 0.8 ; $p=0.7$; figure 3). The mean ACO score (scale 0–3) was 1.2 ± 0.55 in the 1-piece group and 1.2 ± 0.53 in the 3-piece group ($p=0.9$). Post hoc power analysis for the observed SD of 39 patients (78 eyes) showed that a clinically relevant difference in the PCO rate of 0.5 (ie, 5%) could be calculated with 99% power at an α level of 5%. Figure 4 shows three representative cases from our data set.

Concerning capsular bag performance of the IOLs, no significant difference between the groups was found regarding buttonholing of the optic through rhexis (number of cases; 1-piece: 11, 3-piece: 8, $p=0.5$, McNemar Test). None of the eyes showed any significant decentration (more than 0.5 mm of the visual axis and causing visual symptoms). Due to this relatively high incidence of buttonholing, a retrospective subanalysis was performed to assess the influence of buttonholing on visual acuity (VA) and PCO rate. Although there was a trend for the eyes with buttonholing to have a higher PCO rate, this did not reach statistical significance (AQUA score, eyes with buttonholing: 0.49 ± 0.6 , with rhexis-IOL overlap: 0.18 ± 0.4 , $p=0.06$). Concerning subtype of the fibrotic PCO, there was a significantly higher incidence of capsular wrinkling observed in eyes

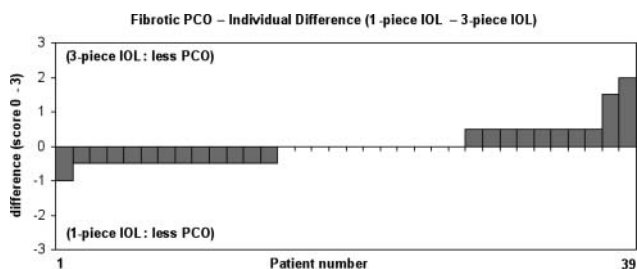


Figure 3 Intraindividual difference fibrotic posterior capsular opacification in all patients (n=39) 1 year after surgery.

with buttonholing (number of cases; eyes with buttonholing: 8/19, eyes with rhexis-IOL overlap: 4/59, $p=0.01$, χ^2 test).

Comparison of capsular folds between the IOL groups showed significantly higher incidence in the 3-piece IOL group (1-piece: 9, 3-piece: 18, $p=0.02$, McNemar test). The capsular folds appeared in 32% (6/19) of all eyes with buttonholing and in 36% (21/59) of all eyes with complete rhexis-IOL overlap ($p=0.8$, χ^2 test). Moreover, eyes with capsular folds showed a slightly higher PCO incidence ($p=0.17$).

The results of UCVA and BCVA are summarised in table 1. There was no statistically significant difference in VA found neither between the IOL groups nor for the subgroups of capsular folds and buttonholing.

DISCUSSION

The present study demonstrates that the modification of the IOL haptic design of an acrylic hydrophobic IOL from a 3-piece to a 1-piece haptic design caused no significant change in PCO, but resulted in a significant decrease in capsular folds rate at 1 year follow-up.

Since both IOLs are made of the same hydrophobic acrylic material and have a similar design (optic size, sharp edge, haptic angulation), any possible differences in PCO rate and capsular bag performance could be explained only by the variation of haptic design.

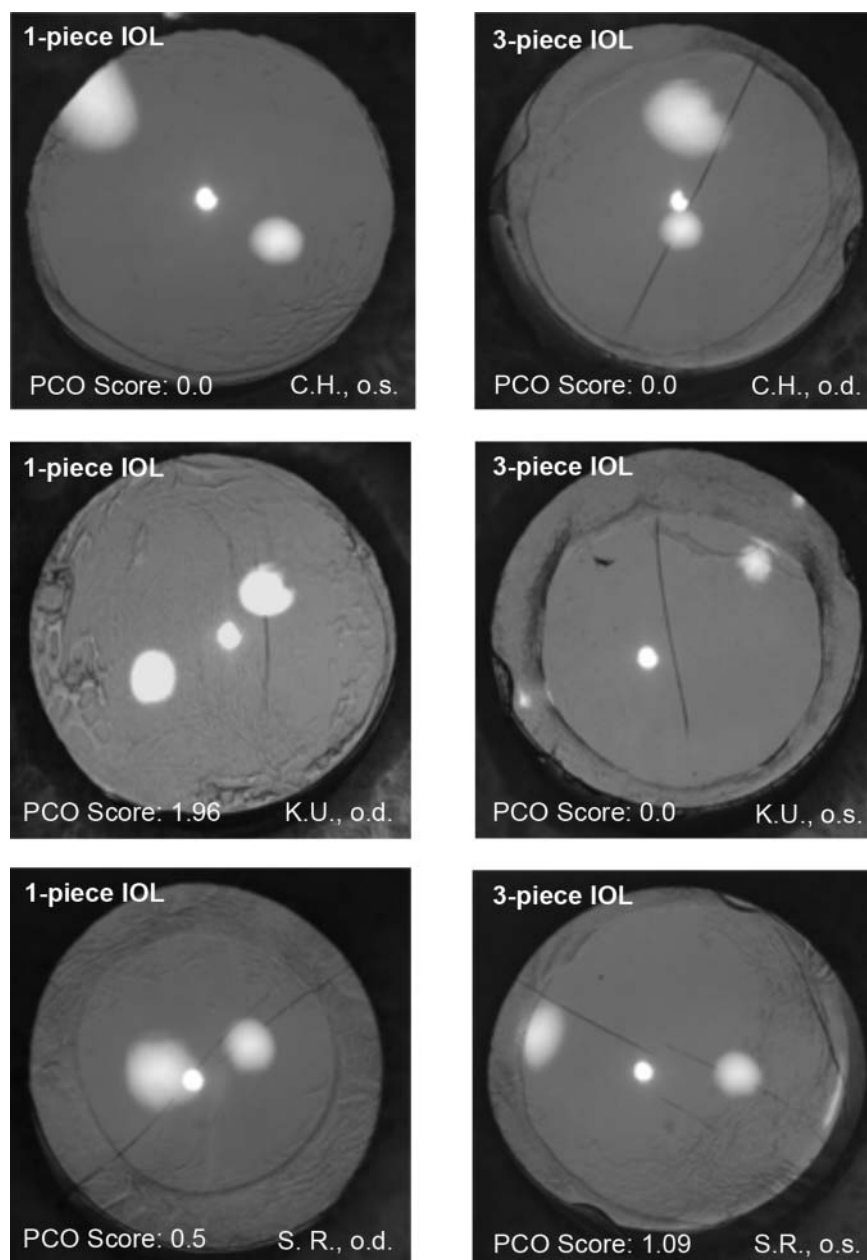
The possible impact of haptic design on PCO prevention is controversial.¹⁵ Wallin *et al*¹⁶ reported a significant increase of PCO rate with a 1-piece AcrySof IOL compared with a 3-piece AcrySof IOL. Another study group, comparing the same IOLs in short and long term follow-up, found a significantly higher PCO rate in the 1-piece IOL group after 1 year follow-up.¹⁷ However, the long term follow-up showed that the PCO and Nd:YAG rate was comparable for both IOLs.¹⁸ The authors suggested that, due to the haptic–optic angulation of the three piece IOL, the better barrier effect was given only in an early postoperative period, but disappeared during the following years.

In contrast to this initially higher PCO incidence of the 1-piece AcrySof IOL, other studies reported a comparable low PCO for both IOLs within the short term follow-up.^{19–21} The stronger binding of fibronectin and laminin to acrylate IOL, as previously reported by Linnola *et al*,²² may be an explanation for the improved adhesion to the haptics of a 1-piece IOL and, thus, for the comparable rate of PCO.

Except for haptic material, the two IOL types are identical. At the short term follow-up, there was no statistical significance either in severity or in type of PCO between the IOLs. A possible explanation for this might be that IOL haptic design does not play a key role in PCO prevention, once a continuous sharp optic edge is given.²³ Another possible explanation is that a unique combination of monoblock open loop haptic design with supplementary PMMA haptic optic protectors of the 1-piece IOL comprises the mentioned benefit from the same strong fibronectin reaction to the optic and haptics and additionally allows an enhanced contact pressure between the optic edge and posterior capsule, inducing a mechanical barrier that prevents cell migration.²⁴

A complete overlap of the capsulorhexis edge with the IOL optic is prone to be an important factor in the prevention of PCO postoperatively.²⁵ Although a complete rhexis-IOL overlap was created at the end of the surgery, we found at 1 year follow-up a relatively high incidence of buttonholing in both IOL groups that caused a significantly greater wrinkling and higher PCO rates in these eyes.

Figure 4 Retroillumination images of three representative patients. Objective automated image analysis software scores of posterior capsular opacification are given for each eye. o. d.=right eye; o. s.=left eye.



Concerning capsular bag performance of both IOLs, the 1-piece IOL group showed significantly less capsular folds than the 3-piece IOL group. The likely reason for this may be that PMMA haptics are stiffer and less compressible than the single piece IOL haptics and therefore produce a greater pressure force towards the equator of the capsule, leading to a capsular

over-tension. In addition capsular folds may produce a scaffold for LEC growth along the fold onto the posterior capsule. In fact our results showed that a slightly higher PCO rate was associated with presence of capsular folds. However this had no influence on VA, likely because the PCO proceeded from the peripheral area behind the IOL optic-haptic junction and had not yet reached the central region around the visual axis in most cases.

There are some limitations of this study that need to be pointed out. Because of short follow-up (only 12 months), relatively low PCO rates associated with hydrophobic IOL material and a small sample size, a definitive PCO comparison cannot be made. Hence, further follow-up is necessary to prove whether the designs are equally protective against PCO.

In conclusion, modification of the MICS IOL from a 3-piece to a 1-piece haptic design caused comparable PCO and Nd:YAG laser treatment rates in the short term follow-up. Compared with the 3-piece IOL, the 1-piece IOL led to significantly less capsular folds 1 year after surgery.

Table 1 UCVA and BCVA of each IOL presented at mean±SD

IOL	1-Piece		3-Piece	
	Preoperative	1-year	Preoperative	1-year
VA (logMAR)				
UCVA (mean±SD)	0.66±0.29	0.21±0.19	0.67±0.32	0.20±0.2
BCVA (mean±SD)	0.25±0.16	0.06±0.13	0.29±0.25	0.06±0.1
p Value*	<0.001	<0.001		

*p Value for difference between preoperative and 1-year postoperative values. BCVA, best corrected distance visual acuity; IOL, intraocular lens; logMAR, logarithm of the minimum angle of resolution; UCVA, uncorrected distance visual acuity.

The authors have no proprietary interest in any of the materials or equipment mentioned in this study. The trial was supported by an unrestricted grant from Hoya.

The Corresponding Author has the right to grant on behalf of all authors and does grant on behalf of all authors, an exclusive licence (or non-exclusive for government employees) on a worldwide basis to the BMJ Publishing Group Ltd to permit this article (if accepted) to be published in BJO and any other BMJPGJL products and sublicences such use and exploit all subsidiary rights, as set out in our licence.

Contributors AP, contribution regarding conception and design, acquisition of data, analysis and interpretation of data, drafting the article and revising it critically for important intellectual content. PVV-M, contribution regarding conception and design, interpretation of data, drafting the article and revising it critically for important intellectual content and final approval of the version to be published. DS, contribution regarding conception and design, interpretation of data, drafting the article and revising it critically for important intellectual content and final approval of the version to be published. PI, contribution regarding conception and design, interpretation of data, drafting the article and revising it critically for important intellectual content and final approval of the version to be published. OF, contribution regarding conception and design, interpretation of data, drafting the article and revising it critically for important intellectual content and final approval of the version to be published. BW, contribution regarding conception and design, interpretation of data, drafting the article and revising it critically for important intellectual content and final approval of the version to be published.

Funding The trial was supported by an unrestricted grant.

Competing interests None.

Patient consent Obtained.

Provenance and peer review Not commissioned; externally peer reviewed.

REFERENCES

- Findl O, Buehl W, Bauer P, *et al.* Interventions for preventing posterior capsule opacification. *Cochrane Database Syst Rev* 2007;(3):CD003738.
- Findl O, Menapace R, Sacu S, *et al.* Effect of optic material on posterior capsule opacification in intraocular lenses with sharp-edge optics: randomized clinical trial. *Ophthalmology* 2005;112:67–72.
- Sacu S, Menapace R, Findl O, *et al.* Influence of optic edge design and anterior capsule polishing on posterior capsule fibrosis. *J Cataract Refract Surg* 2004;30:658–62.
- Vock L, Georgopoulos M, Neumayer T, *et al.* Effect of the hydrophilicity of acrylic intraocular lens material and haptic angulation on anterior capsule opacification. *Br J Ophthalmol* 2007;91:476–80.
- Buehl W, Findl O, Menapace R, *et al.* Long-term effect of optic edge design in an acrylic intraocular lens on posterior capsule opacification. *J Cataract Refract Surg* 2005;31:954–61.
- Alio JL, Rodriguez-Prats JL, Vianello A, *et al.* Visual outcome of microincision cataract surgery with implantation of an Acri. Smart lens. *J Cataract Refract Surg* 2005;31:1549–56.
- Hayashi K, Yoshida M, Hayashi H. Postoperative corneal shape changes: microincision versus small-incision coaxial cataract surgery. *J Cataract Refract Surg* 2009;35:233–9.
- Masket S, Wang L, Belani S. Induced astigmatism with 2.2- and 3.0-mm coaxial phacoemulsification incisions. *J Refract Surg* 2009;25:21–4.
- Gangwani V, Hirschall N, Koshy J, *et al.* Posterior capsule opacification and capsular bag performance of a microincision intraocular lens. *J Cataract Refract Surg* 2011;37:1988–92.
- Kaya V, Ozturker ZK, Ozturker C, *et al.* ThinOptX vs AcrySof: comparison of visual and refractive results, contrast sensitivity, and the incidence of posterior capsule opacification. *Eur J Ophthalmol* 2007;17:307–14.
- Prakash P, Kasaby HE, Aggarwal RK, *et al.* Microincision bimanual phacoemulsification and Thinoptx implantation through a 1.70 mm incision. *Eye (Lond)* 2007;21:177–82.
- Pande MV, Ursell PG, Spalton DJ, *et al.* High-resolution digital retroillumination imaging of the posterior lens capsule after cataract surgery. *J Cataract Refract Surg* 1997;23:1521–7.
- Buehl W, Findl O, Menapace R, *et al.* Reproducibility of standardized retroillumination photography for quantification of posterior capsule opacification. *J Cataract Refract Surg* 2002;28:265–70.
- Findl O, Buehl W, Menapace R, *et al.* Comparison of 4 methods for quantifying posterior capsule opacification. *J Cataract Refract Surg* 2003;29:106–11.
- Chang DF. Single versus three piece acrylic IOLs. *Br J Ophthalmol* 2004;88:727–8.
- Wallin TR, Hinckley M, Nilson C, *et al.* A clinical comparison of single-piece and three-piece truncated hydrophobic acrylic intraocular lenses. *Am J Ophthalmol* 2003;136:614–19.
- Sacu S, Findl O, Menapace R, *et al.* Comparison of posterior capsule opacification between the 1-piece and 3-piece Acrysof intraocular lenses: two-year results of a randomized trial. *Ophthalmology* 2004;111:1840–6.
- Leydolt C, Davidovic S, Sacu S, *et al.* Long-term effect of 1-piece and 3-piece hydrophobic acrylic intraocular lens on posterior capsule opacification: a randomized trial. *Ophthalmology* 2007;114:1663–9.
- Nejima R, Miyata K, Honbou M, *et al.* A prospective, randomised comparison of single and three piece acrylic foldable intraocular lenses. *Br J Ophthalmol* 2004;88:746–9.
- Nejima R, Miyai T, Kataoka Y, *et al.* Prospective intrapatient comparison of 6.0-millimeter optic single-piece and 3-piece hydrophobic acrylic foldable intraocular lenses. *Ophthalmology* 2006;113:585–90.
- Bender LE, Nimsgern C, Jose R, *et al.* Effect of 1-piece and 3-piece AcrySof intraocular lenses on the development of posterior capsule opacification after cataract surgery. *J Cataract Refract Surg* 2004;30:786–9.
- Linnola RJ, Werner L, Pandey SK, *et al.* Adhesion of fibronectin, vitronectin, laminin, and collagen type IV to intraocular lens materials in pseudophakic human autopsy eyes. Part 2: explanted intraocular lenses. *J Cataract Refract Surg* 2000;26:1807–18.
- Kohnen T, Fabian E, Gerl R, *et al.* Optic edge design as long-term factor for posterior capsular opacification rates. *Ophthalmology* 2008;115:1308–14, 1314 e1–3.
- Boyce JF, Bhermi GS, Spalton DJ, *et al.* Mathematical modeling of the forces between an intraocular lens and the capsule. *J Cataract Refract Surg* 2002;28:1853–9.
- Hollic EJ, Spalton DJ, Meacock WR. The effect of capsulorhexis size on posterior capsular opacification: one-year results of a randomized prospective trial. *Am J Ophthalmol* 1999;128:271–9.



Comparison of posterior capsule opacification between a 1-piece and a 3-piece microincision intraocular lens

Ana Prinz, Pia Veronika Vecsei-Marlovits, Dietrich Sonderhof, et al.

Br J Ophthalmol 2013 97: 18-22 originally published online September 5, 2012

doi: 10.1136/bjophthalmol-2012-301899

Updated information and services can be found at:

<http://bjo.bmj.com/content/97/1/18.full.html>

These include:

References

This article cites 24 articles, 3 of which can be accessed free at:

<http://bjo.bmj.com/content/97/1/18.full.html#ref-list-1>

Email alerting service

Receive free email alerts when new articles cite this article. Sign up in the box at the top right corner of the online article.

Topic Collections

Articles on similar topics can be found in the following collections

[Lens and zonules](#) (677 articles)

Notes

To request permissions go to:

<http://group.bmj.com/group/rights-licensing/permissions>

To order reprints go to:

<http://journals.bmj.com/cgi/reprintform>

To subscribe to BMJ go to:

<http://group.bmj.com/subscribe/>